

SUCCESSFUL MANAGEMENT OF IDIOPATHIC REFRACTORY TRIGEMINAL'S THIRD BRANCH NEURALGIA IN ELDERLY PATIENT WITH INFERIOR ALVEOLAR NERVE RADIOFREQUENCY

Andrea Fanelli MD¹, Eleonora Balzani MD², and Rita Maria Melotti PhD^{1,3}

Background: Pulse-dose radiofrequency (PDRF) treatment is a minimally invasive alternative to continued and pulsed radiofrequency (PRF) treatment in chronic pain management. Although there is evidence in the literature of treatment for unresponsive trigeminal neuralgia (TN) with PRF, there is no proven efficacy for PDRF.

Case Report: We present a case of idiopathic refractory TN in an elderly patient treated with PDRF, since the patient appeared intolerant and unresponsive to pharmacological therapy. Three treatment sessions were given with a follow-up of 6 months. PDRF treatment was administered as long as the patient reported the exacerbation of the pain, in contrast to our standard clinical practice.

Conclusions: A long-term effect and a dose-cumulative effect were seen in our patient, with a complete remission of the pain symptomatology. No neurological side effects or complications were reported.

Key words: Inferior alveolar nerve radiofrequency, pain therapy, pulse-dose radiofrequency, trigeminal neuralgia

BACKGROUND

Trigeminal neuralgia (TN) is defined by paroxysmal, stereotyped attacks of intense, sharp pain in the distribution of one or more branches of the fifth cranial nerve (1). TN can be classified as classic TN, secondary TN caused by an underlying disease (multiple sclerosis, tumor along the trigeminal nerve), or idiopathic. The diagnostic criteria for TN are explained by the International Classification of Headache Disorders, Third Edition (2). To diagnose classic and symptomatic TN, a physical examination, medical and dental history, and neuroimaging of the head with magnetic resonance imaging (MRI) are necessary (3,4).

Carbamazepine (CBZ) is the first-step treatment drug. A high number of patients receive multiple treatments

due to suboptimal efficacy of CBZ and its tolerability, leading to drug switching (5). Surgery and radiofrequency therapy are considered when the pain becomes unresponsive. Other techniques such as microvascular decompression could be appropriate in the case of low anesthesiological risk, and age less than 70 years in the case of failure of medical therapy.

Refractory neuralgia, which does not benefit from conservative treatments, is approached with neurodestructive methods. These techniques have numerous side effects such as tissue fibrosis, formation of neuroma, and necrosis (6).

Pulsed radiofrequency (PRF) was introduced despite its documented reduced efficacy (7) compared to radiofrequency thermocoagulation (RFTC), since it has fewer

From: ¹Anesthesia and Pain Medicine Unit, Department of Emergency and Urgency, Policlinico S. Orsola-Malpighi Hospital, Bologna, Italy; ²Department of Surgical Sciences, University of Torino, Torino, Italy; ³Department of Medical and Surgical Sciences, University of Bologna, Bologna, Italy

Corresponding Author: Eleonora Balzani, MD, E-mail: eleonora.balzani2@gmail.com

Disclaimer: There was no external funding in the preparation of this manuscript.

Conflict of interest: Each author certifies that he or she, or a member of his or her immediate family, has no commercial association (i.e., consultancies, stock ownership, equity interest, patent/licensing arrangements, etc.) that might pose a conflict of interest in connection with the submitted manuscript.

Accepted: 2020-10-16, Published: 2021-05-31

neurodestructive effects (8). Although PRF efficacy on the Gasserian ganglion has been assessed, it is not well described for the distal trigeminal branches; only 5 case reports (8-10) and 2 studies (11,12) have been reported. Case reports analyze both V3 and V2 chronic pain. One study compares monopolar to bipolar radiofrequency; the other one evaluates a PRF approach in infraorbital nerve neuralgia. All of the 5 case reports agree with a step-up approach, starting from nerve block with an ultrasound guide (USG) (10-12 MHz), injecting a mixture of local anesthetic (e.g., mepivacaine) and corticosteroids (e.g., triamcinolone), and ending with USG PFR. This latter procedure requires confirmation of the needle position under fluoroscopy. Four of 5 cases did not need any further medication after PRF. There is no evidence regarding PDRF's benefits for TN; for this reason, choosing the radiofrequency dosage without guidelines or clinical evidence proves to be a significant limitation in the clinical use of PDRF. Here, we report a case of refractory idiopathic TN that was successfully treated with PRF with a dose-cumulative effect on the inferior alveolar nerve.

CASE PRESENTATION

The patient is an 85-year-old woman diagnosed with TN. The patient had a history of constant bilateral ache of the mandibular area initially located in the third branch of the left trigeminal nerve. No paresthesia was reported. The pain interfered with speech and feeding but not with sleep. When she was referred to the pain clinic, she described her pain as sharp and intense. She reported a history of chronic obstructive pulmonary disease, previous *Mycobacterium tuberculosis* infection, hypertension, hypothyroidism, and chronic atrial fibrillation for which, at the time of our evaluation, she was taking direct oral anticoagulants (edoxaban), β 1-blockers, digoxin, furosemide, ramipril, levothyroxine, and levosulpiride.

Dental pain, nasal cavity pathologies, as well as inflammation of the temporomandibular joint or tonsils and pharynx were excluded as they could cause pain in the same region. An MRI was conducted to exclude structural lesions (13,14) and no pathological signs were reported. All physical examinations, including that of the cranial nerves, were normal.

The patient had tried multiple combinations of medications including CBZ, gabapentin, pregabalin, tapentadol, and topiramate with no significant relief from either monotherapy or in combination with

other medications. She also tried acupuncture and cannabinoids.

Due to the high bleeding risk from direct oral anti-coagulants therapy, PRF on the Gasserian ganglion was ruled out as a possible treatment strategy. Based on her presentation, she was scheduled for inferior alveolar nerve ganglion block with 1.5 mL of lidocaine 2%. After 5 minutes she reported complete remission. Based on these observations, we decided to proceed with PRF in order to provide long-term pain relief.

The patient was placed supine. After having identified via surface marker the pterygomandibular muscle raphe and pterygomandibular depression, the needle was placed in the area between them, at the level of the coronoid notch of the anterior border of the mandible's ramus (see Fig. 1 for further details).

At this stage, the radiofrequency needle tip was stimulated to exclude paresthesia and sensory nerve alterations. PDRF supply was given by the NeuroTherm NT1100™ radiofrequency generator. After a positive sensory test (50 Hz), PDRF was performed at a voltage of 45 V, 20 milliseconds, and 2 PPS. Keeping the temperature below 42°C, 1200 pulses were applied to the inferior alveolar nerve before it enters into the mandibular foramen to reach the mandibular canal. No drugs were added after the procedure and no discomfort or local reactions were reported.

One month after the procedure, during the follow-up visit, she reported fewer exacerbations and a reduction of the intensity and the area involved. We decided to proceed with a second PDRF session (1200 pulses, 45 V, 20 milliseconds, 2 PPS) since the patient was still symptomatic and every medication taken before had failed (see Fig. 2). The radiofrequency treatment was repeated every 2 months, thus completing 3 PDRF treatment sessions over a period of 4 months. PDRF sessions were progressively improved each time by reducing the pain's site extension and the number of pain exacerbations. During the last treatment session, to further treat the neuropathic pain symptoms, 25 mg of pregabalin was prescribed once a day for the first 3 days, twice a day from the fourth day, and 3 times a day from the seventh day onward.

After PDRF treatment, at a 6-month follow-up, the patient reported complete remission of her chronic pain so that she was able to use dental prostheses. Occasional paresthesias lasting about 2 minutes were also reported.

Her current pharmacological maintenance treatment is pregabalin 25 mg 3 times a day. At the 6-month

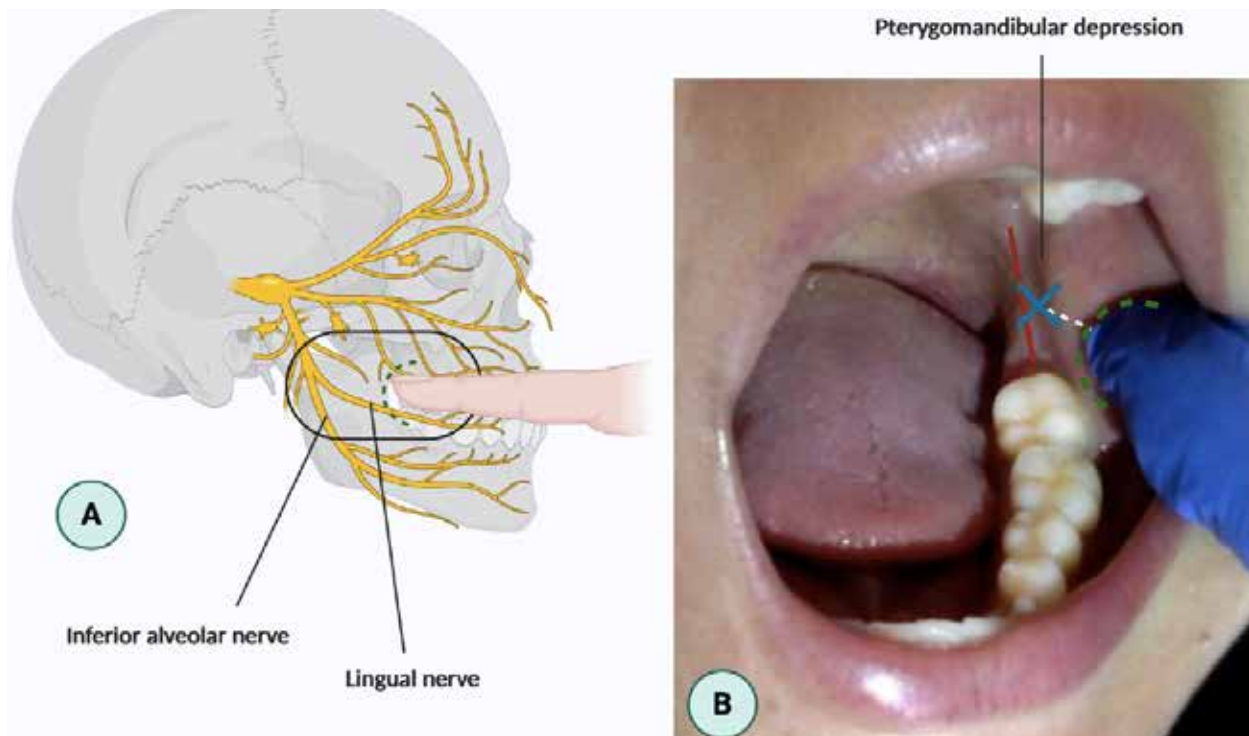


Fig. 1. The image shows how to identify the point where we performed the PDRF. Image A shows where the coronoid notch is located and how to place the finger during the maneuver inside the buccal ostium. The same image shows the innervation passing through that region. The lingual nerve contracts close relationships with the alveolar nerve, making it possible to anesthetize a portion of the tongue. In image B, the points of reference are shown. The green dotted line corresponds to the coronoid notch. The red line emphasizes the pterygomandibular raphe, and the pterygomandibular depression is clearly visible in the image.

Identifying as the vertical line the space between the pterygomandibular raphe and pterygomandibular depression, and identifying as the horizontal line a segment that originates from the midpoint of the finger placed on the coronoid notch to the vertical line, we find in the intersection the injection point to conduct the lower alveolar nerve block. (Created with BioRender.com)

follow-up, she expressed her satisfaction with pain relief given from the PDRF treatment.

DISCUSSION AND CONCLUSION

PDRF is a technical improvement over PRF, although its mechanism of action on the pain signaling process is expected to be similar for both methods (15). PDRF enables consecutive pulses at the same pulse amplitude and width, keeping the area under the limit of tissue thermocoagulation. In PDRF, every pulse has the same characteristics as the previous one, allowing standardization of received doses and its reproducibility (15). PDRF's neuromodulation produces nerve repolarization and inhibits excitatory C fiber response (16). The main difference between the 2 methods is that PDRF maintains the tissue temperature below 42°C. In PRF,

an increased tissue temperature beyond 42°C causes impulse modification in amplitude or voltage; in PDRF, when that temperature is reached, the following impulse is not dispensed, resuming delivery of pulses when the temperature drops below 42°C (15).

Scientific literature guidelines do not show a correlation between dose and pathology. In a standard-voltage PRF, the alternating current has an impulse frequency of 2 Hz, and an output voltage of 45 V (17); however, a study conducted by Luo et al (18) showed that TN has better outcomes when treated with high-voltage PRF rather than standard-voltage PRF. The mechanisms underlying a better pain relief effect remain unclear, one of which probably includes changes in dorsal horn c-fos, even if the latter changes do not represent a specific marker (19). In infraorbital nerve neuralgia treated with

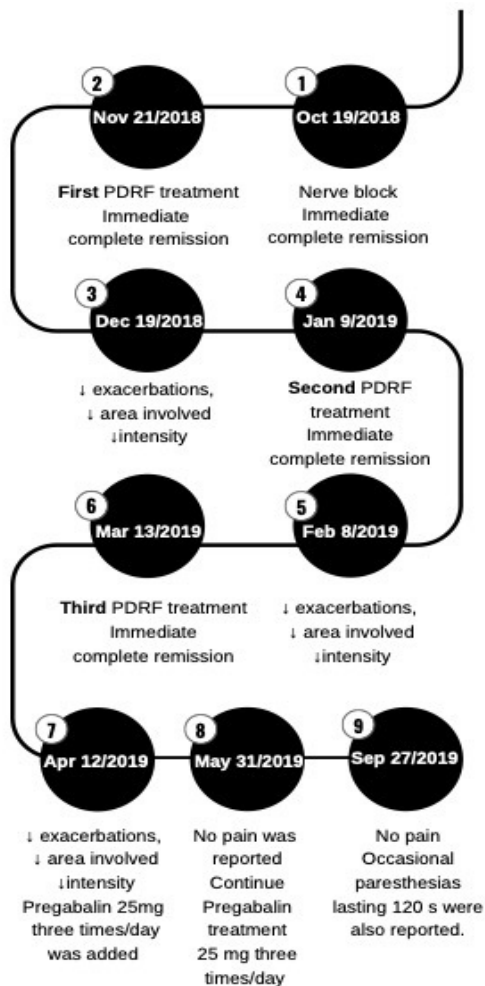


Fig. 2. Timing of PDRF treatment, clinical outcomes, and follow-up. A period from October 2018 to September 2019 was taken into consideration.

Abbreviation: PDRF, pulse-dose radiofrequency

pulsed radiofrequency, one-month, 3-month, 6-month, and 2-year efficacy checks are suggested (12). An add-on treatment for those who do not respond to the standard therapy is also required in every follow-up (18).

In our case of TN treated with PDRF, both the extension of the pain symptomatology and the number of exacerbations were reduced with a cumulative overall effect that may suggest different underlying physiological mechanisms and outcomes between PDRF and other radiofrequency treatments. Repetitive treatment could raise the total radiofrequency dose with an additive process altering nerve conduction.

Reducing symptomatology plays an important role in an elderly population, since patients without teeth and therefore with difficulty in eating solid food with TN can lose a considerable amount of weight in a short time, exposing them to sarcopenia.

This case report described an alternative approach to TN using PDRF in a dose-cumulative way. Since the scientific literature does not provide PDRF treatment guidelines for similar patients, we look forward to a clinical trial in the future even if the paucity of cases makes it very hard to have a substantial number of patients.

Authors' Contributions

A.F. wrote the manuscript and designed the study, E.B. wrote the manuscript and constructed figures. R.M.M reviewed and edited the manuscript. All authors read and approved the final manuscript.

REFERENCES

1. Ho CC, Khan SA, Whealy MA. Trigeminal neuralgia. UpToDate Web site. www.uptodate.com/contents/trigeminal-neuralgia. Date Updated 10/12/2020. Date Accessed 10/12/2020.
2. The International Classification of Headache Disorders 3rd edition. IHS Classification ICHD-3 Web site. www.ichd-3.org. Date Updated 10/12/2020. Date Accessed 10/12/2020.
3. Khan M, Nishi SE, Hassan SN, Islam MA, Gan SH. Trigeminal neuralgia, glossopharyngeal neuralgia, and myofascial pain dysfunction syndrome: An update. *Pain Res Manag* 2017; 2017:7438326.
4. Gronseth G, Cruccu G, Alksne J, et al. Practice parameter: The diagnostic evaluation and treatment of trigeminal neuralgia (an evidence-based review): report of the Quality Standards Subcommittee of the American Academy of Neurology and the European Federation of Neurological Societies. *Neurology* 2008; 71:1183-1190.
5. Zakrzewska JM, Wu N, Lee JYK, Werneburg B, Hoffman D, Liu Y. Characterizing treatment utilization patterns for trigeminal neuralgia in the United States. *Clin J Pain* 2018; 34:691-699.
6. Wójcik SA, Waškowska JA, Koszowski RT. Powikłanie po alkoholizacji nerwu bródkowego [Complications after alcoholization of mental nerve]. *Wiad Lek* 2008; 61:243-245.
7. Fang L, Ying S, Tao W, Lan M, Xiaotong Y, Nan J. 3D CT-guided pulsed radiofrequency treatment for trigeminal neuralgia. *Pain Pract* 2014; 14:16-21.
8. Nguyen M, Wilkes D. Pulsed radiofrequency V2 treatment and intranasal sphenopalatine ganglion block: A combination therapy for atypical trigeminal neuralgia. *Pain Pract* 2010; 10:370-374.
9. Park HG, Park PG, Kim WJ, et al. Ultrasound-assisted mental nerve block and pulsed radiofrequency treatment for intractable postherpetic neuralgia: Three case studies. *Korean J Pain* 2014; 27:81-85.
10. Lim SM, Park HL, Moon HY, et al. Ultrasound-guided infraorbital nerve pulsed radiofrequency treatment for intractable postherpetic neuralgia - a case report. *Korean J Pain* 2013; 26:84-88.
11. Huang B, Xie K, Chen Y, Wu J, Yao M. Bipolar radiofrequency ablation of mandibular branch for refractory V3 trigeminal neuralgia. *J Pain Res* 2019; 12:1465-1474.
12. Luo F, Lu J, Shen Y, Meng L, Wang T, Ji N. Effectiveness and safety of pulsed radiofrequency treatment guided by computed tomography for refractory neuralgia of infraorbital nerve: A pilot study. *Pain Physician* 2015; 18:E795-E804.
13. Goh BT, Poon CY, Peck RH. The importance of routine magnetic resonance imaging in trigeminal neuralgia diagnosis. *Oral Surg Oral Med Oral Pathol Oral Radiol Endod* 2001; 92:424-429.
14. Borges A, Casselman J. Imaging the trigeminal nerve. *Eur J Radiol* 2010; 74:323-340.
15. Ojango C, Raguso M, Fiori R, Masala S. Pulse-dose radiofrequency treatment in pain management-initial experience. *Skeletal Radiol* 2018; 47:609-618.
16. Cahana A, Van Zundert J, Macrea L, van Kleef M, Sluijter M. Pulsed radiofrequency: Current clinical and biological literature available. *Pain Med* 2006; 7:411-423.
17. Snidvongs S, Mehta V. Pulsed radio frequency: A non-neurodestructive therapy in pain management. *Curr Opin Support Palliat Care* 2010; 4:107-110.
18. Luo F, Wang T, Shen Y, Meng L, Lu J, Ji N. High voltage pulsed radiofrequency for the treatment of refractory neuralgia of the infraorbital nerve: A prospective double-blinded randomized controlled study. *Pain Physician* 2017; 20:271-279.
19. Bogduk N. Pulsed radiofrequency. *Pain Med* 2006; 7:396-407.

