

# **EFFECTIVE TREATMENT OF FACIAL AND HEADACHE PAIN WITH HIGH CERVICAL BURST SPINAL CORD STIMULATION: TWO CASE REPORTS**

Javid Baksh, DO

**Background:** Atypical facial pain and chronic headache conditions may involve the dysfunction of one or more cranial and/or spinal nerves and dramatically impede quality of life. Pain management for these cases may be complicated, especially when medication options are limited. Neuromodulation may be considered for intractable cases. Here, we present our experience with a novel application of neuromodulation that may harness a common mechanism for the treatment of cranial/facial pain.

**Case Report:** Case 1 presented with alveolar neuralgia triggered by eating or drinking and causing headaches in the upper cervical and facial area. Case 2 presented with chronic daily headaches. Both received spinal cord stimulation (SCS) implants with leads at C3-C4 using BurstDR stimulation. After several months of treatment, Case 1 was once again able to eat while nearly 100% pain free with complete cessation of pain medication. Case 2 reported that his headache frequency decreased to approximately twice per month, allowing a 90% decrease in pain medication and improvement in quality of life.

**Conclusion:** Reasons for excellent pain relief of alveolar neuralgia pain and chronic headache pain via burst SCS at C3-C4 could be the overlap of nerve systems and their convergence at the trigeminocervical complex in the cervical spine. This may explain the effectiveness of high cervical stimulation to treat facial and headache pain located outside of the typical boundaries of the recruited fibers. Although a single-electrode array proved to be efficacious, using 2 electrode arrays improves the anatomic coverage of the painful areas and allows for greater optionality in electrode selections to avoid plasticity.

**Key words:** Burst, BurstDR, dorsal column stimulation, facial pain, headache, nerve pain, nerve stimulation, neuropathic pain, spinal cord stimulation

## **BACKGROUND**

Facial pain is estimated to affect 38.7 people per 100,000 and considerably impacts quality of life (1). Atypical facial pain, in which the site of pain is poorly localized and is not strictly aligned with anatomical distributions, is more complicated; these pain conditions may involve more than one nerve (2). Similarly, the pain associated with chronic headache conditions may involve the dysfunction of one or more cranial nerves

and dramatically impede quality of life (3,4), with an estimated 4% of adults suffering recurrent episodes on more than half of days (5).

Pain management for these cases may be complicated and require an algorithm of nonpharmacologic treatments, escalating medications, and prophylactics. A series of injections in the head and/or neck may also be helpful (6). However, patients may have contraindications to such a regimen, be unable to tolerate side ef-

From: Premier Pain Solutions, Asheville, North Carolina

Corresponding Author: Javid Baksh, DO, E-mail: jbaksh34@gmail.com

Disclaimer: There was no external funding in the preparation of this manuscript.

Conflict of interest: Dr. Baksh is a speaker for Abbott Medical, Flowonix Medical, Basic Home Infusion, Inc., and Paradigm Labs.

Accepted: 2020-09-24, Published: 2021-05-31

fects, and/or prefer to avoid habit-forming medications. Behavioral or lifestyle-modification interventions alone may have limited utility (7,8), leaving patients with few remaining options.

Neuromodulation may be considered for intractable facial and headache pain cases. For some, peripheral nerve stimulation is selected, with leads placed along the affected nerve for facial pain or at the occiput in headache cases (9,10). However, the surgical preparations for these cases can require a great deal of nuance (11-13), and patients may dislike having subcutaneous leads traversing their head and neck to reach the implantable pulse generator (IPG) in the subclavicular space or another region.

Another form of neuromodulation, spinal cord stimulation (SCS), which is more commonly undertaken for cases of intractable neuropathic trunk and limb pain, involves inserting leads longitudinally into the spinal epidural space to recruit afferent fibers in the dorsal column of the spinal cord. Electrical stimulation is then delivered in regular tonic, phasic bursting, high-frequency, or other patterns (14). The selection of waveform is generally predicated on pain locations and presentations. Although serious risks such as dural puncture and epidural hematoma exist for SCS, they occur very infrequently (15). Lead positioning within the spinal cord may be more acceptable to patients than that of peripheral nerve stimulation. Because the C2-C4 dermatomes include portions of the head and neck (16), SCS may be another option for craniofacial pain. Specific to headache and facial pain, a number of small series have reported beneficial effects with SCS using leads placed in the high cervical space (C1-C4). For example, in a cohort of 17 migraine patients who were followed for a median of 15 months, the median number of headache days per month decreased from 28 to 9, with their pain intensity reduced by 60% (17). Similarly, in a group of 7 patients with cluster headache who were treated for 3 to 78 months (mean, 23 months), all reported reductions in the frequency, duration, and/or intensity of their pain episodes (18). For 12 patients with trigeminal neuralgia, 9 of whom continued with cervical SCS over a mean follow-up of 4 years, the average pain relief was 57.1% (19). Newer waveforms have also been employed, to good effect. High-frequency SCS at high cervical levels resulted in at least 30% reduction in the number of headache days for half of the sample of 14; those 7 patients experienced, on average, 12.9 fewer headache days per month (20). In another small

report of high-frequency cervical SCS across a number of headache etiologies, 6 out of 7 patients had at least 50% reduction in the frequency and/or intensity of their headaches at an average of 28 months of treatment (21).

In addition to high-frequency SCS, BurstDR™ SCS is another recently-developed waveform and has demonstrated superiority to conventional tonic SCS in trunk and limb pain (22). The effect of high cervical burst SCS for intractable headache or facial pain is not known. Recently, we implanted SCS systems in 2 patients who complained of facial/headache pain, as well as spinal/radicular pain in cervical distributions. To ensure therapeutic coverage of all pain regions (craniofacial, neck, and upper limbs), leads were placed at a high cervical level: C2-4. Here, we present the details of those cases, their clinical outcomes to date, and hypothesize on the neural mechanisms that may underlie these observations.

## **METHODS**

After receiving patients' informed consent, we retrospectively reviewed the case notes.

## **RESULTS**

### **Case 1**

The patient, a 55-year-old man, presented with chronic neuropathic gum pain triggered by eating or drinking and causing headaches in the upper cervical and facial area. In addition, he reported ongoing neck pain and upper limb radiculopathy. His facial pain was rated 7 to 8 on a standard 10-cm Visual Analog Scale (VAS) and described as nagging/throbbing. Previous use of membrane-stabilizing agents delivered limited improvements with varying side effects, and the patient wanted to avoid the use of opioid medications. To manage the pain, he stopped eating as much and was losing weight.

The diagnosis was atypical facial pain consistent with alveolar neuralgia. An alveolar nerve block (dexamethasone/lidocaine) was performed, to good but temporary effect (2-3 days). There was also a return of pain following radiofrequency ablation at the affected levels, although it delivered longer-lasting pain relief and functional improvement (10 days). The patient continued to rely on analgesics and erenumab injections. A neuromodulation trial (Octrode leads; Abbott, Plano, TX, USA) was then performed with octopolar leads placed at C3-C4 and complete pain-paresthesia

concordance (neck, arms, and face) confirmed intraoperatively (see Fig. 1). After several days with BurstDR stimulation (40 Hz interburst frequency) at subperception amplitudes, there was 80% to 100% pain relief, improved ability to eat, and less need for medication. A permanent SCS system (Proclaim SCS; Abbott, Plano, TX, USA) was then placed. No further pain procedures or prescription pain medications have been required since that time. The patient has once again been able to eat and has reported increased quality of life and high level of satisfaction. After a month of treatment, the patient reported that his pain had decreased by 80% to 100% since beginning SCS treatment, with a VAS score of 1 or 2 out of 10, with complete cessation of pain medication. The patient described himself as “ecstatic” about having the procedure done, and that it “changed his life.” Several months after implantation, he returns to the clinic as needed as he is nearly 100% pain-free.

## Case 2

The patient, a 71-year-old man, presented with neck pain and upper limb pain for which he relied on tramadol (50 mg, 4 times a day) and other pain medications. He also complained of chronic daily headaches. Following a successful SCS trial, a permanent SCS system (Proclaim SCS; Abbott, Plano, TX, USA) was placed with leads at C3-C4 and programmed with the BurstDR waveform at an amplitude that did not generate perceptible paresthesias. Within 2 weeks, the patient reported that 80% to 100% of his neck and arm pain was relieved, reduced to a pain score of approximately 3 out of 10. The patient expressed that the medications allowed him to perform daily activities and it improved his quality of life. Opioid-sparing strategies were discussed. With SCS treatment, the patient voluntarily decreased his pain medication intake by halving it after one month and decreasing to occasional as-needed use after 2 months (more than 90% reduction). At this point, the patient reported that the SCS device covered all of his painful areas and was working well to relieve his cervical radiculopathy pain. It allowed for improvements in daily activities and social/family outings. He also noted that, since receiving the SCS implant, his headache frequency decreased to approximately once every 2 weeks.

## DISCUSSION

These 2 case reports illustrate that BurstDR SCS at C3-C4 resulted in relief of alveolar neuralgia facial pain and of chronic headache pain. The affected nerves were

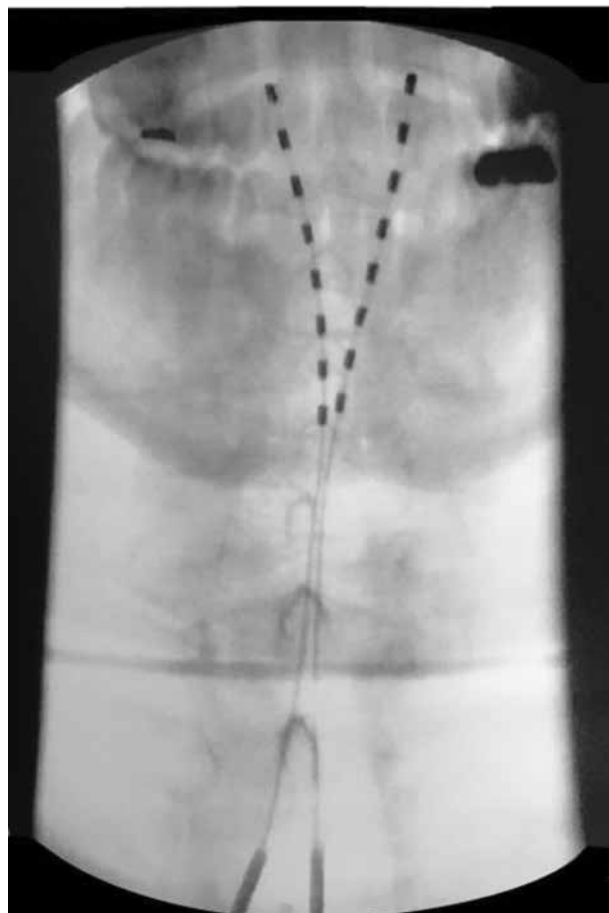


Fig. 1. Percutaneous leads were placed at C3-C4 for the treatment of atypical facial pain as well as neck and upper limb pain.

putatively the alveolar branch of the trigeminal nerve (fifth cranial nerve), and the greater occipital nerve (a branch of the C2 dorsal ramus), respectively. SCS, compared to peripheral nerve stimulation (PNS), was the preferable neuromodulation option in these cases because it avoided surgical interventions directly at the nerve sites, and was also able to treat the concomitant neck and limb pain complaints with the same device.

It is likely that cervical SCS was useful in these cases because the relevant craniofacial afferent nerves converge with somatic afferents at the cervical spinal cord. Convergence has been demonstrated via stimulation of the greater occipital nerve, which activates second-order neurons in the cervical spinal cord (23), alterations in cervical nociceptive neurons following dural stimulation (24), and activation of cervical neurons due to stimulation of trigeminal nerve afferents (25). This neural

convergence can lead to referred pain syndromes in which pain is perceived in the facial or cranial distributions, but is due to neck activity or trauma (26). A report of trigeminal sensory neuropathy caused by cervical disk herniation (27) is a prime example, along with the existence of cervicogenic headaches that are elicited by a source of pain in the neck (28). Furthermore, SCS stimulation at the C3-4 level was shown to cause newly appeared headaches consisting of constant mild pain with intermittent severe episodes (29). Logically, then, it would follow that the converse would also hold true, in that the effectiveness of cervical SCS for headache or facial pain conditions would harness those converging neural pathways.

Indeed, the trigeminocervical complex and its role in headache and neck pain have been well described (33-33). Neurons in the trigeminocervical complex comprise the trigeminal nucleus caudalis in the upper cervical spine and receive converging afferents from trigeminal nerve afferents as well as cervical inputs (28,30,34). In animal models, it has been demonstrated that trigeminal ganglion cells project to the middle cerebral artery and the forehead (35). In the cervical (C1-C4) dorsal spinal cord, lamina I neurons receive A $\delta$  and C-fiber afferents from trigeminal distributions and are activated by glutamate (25). Trigeminal neurons are inactivated by GABA (36), which is similar to the mechanisms for burst SCS (37,38).

This report is the first documenting the effectiveness of burst SCS at the cervical level for craniofacial pain. Burst SCS appears to have the same effectiveness as conventional tonic stimulation, as reviewed above, without perceptible paresthesias at standard treatment settings. Burst SCS may also have similar effectiveness profiles as another paresthesia-free waveform, high-frequency SCS, but at a small fraction of its energy output, which may have favorable implications for the neural electrical dosage and battery consumption.

Although preliminary in case report format, our findings suggest that BurstDR stimulation at the cervical level is an effective treatment for facial and headache pain, and that this neuromodulation intervention permissively harnesses the trigeminocervical complex to have its effects despite lead placement outside of the typical boundaries of the involved afferent fibers. This has further implications for treating other forms of facial/cranial pain and may be another clinical option for these intractable conditions.

#### Authorship Statement

The author made a substantial contribution to the study's concept and design and approved the final version of the manuscript. The author thanks Allison Foster, PhD, an independent medical writer, for her intellectual contribution to the drafting of the manuscript.

#### REFERENCES

1. Koopman JSHA, Dieleman JP, Huygen FJ, de Mos M, Martin CGM, Sturkenboom MCJM. Incidence of facial pain in the general population. *Pain* 2009; 147:122-127.
2. Lascelles RG. Atypical facial pain and depression. *Br J Psychiatry* 1966; 112:651-659.
3. Colas R, Munoz P, Temprano R, Gomez C, Pascual J. Chronic daily headache with analgesic overuse. *Neurology* 2004; 62:1338-1342.
4. Wang SJ, Fuh JL, Lu SR, Juang KD. Quality of life differs among headache diagnoses: Analysis of SF-36 survey in 901 headache patients. *Pain* 2001; 89:285-292.
5. Lipton RB. Tracing transformation: Chronic migraine classification, progression, and epidemiology. *Neurology* 2009; 72:S3-S7.
6. Bendtsen L, Birk S, Kasch H, et al. Reference programme: Diagnosis and treatment of headache disorders and facial pain. Danish Headache Society, 2nd Edition, 2012. *J Headache Pain* 2012; 13:1-29.
7. Goadsby PJ. Migraine: Diagnosis and management. *Intern Med J* 2003; 33:436-442.
8. Bag B, Karabulut N. Pain-relieving factors in migraine and tension-type headache. *Int J Clin Pract* 2005; 59:760-763.
9. Klein J, Sandi-Gahun S, Schackert G, Juratli TA. Peripheral nerve field stimulation for trigeminal neuralgia, trigeminal neuropathic pain, and persistent idiopathic facial pain. *Cephalalgia* 2016; 36:445-453.
10. Weiner RL, Alo KM. Occipital nerve stimulation for treatment of intractable headache syndromes. In: Krames ES, Peckham PH, Rezaei AR (eds). *Neuromodulation*. 2nd ed. New York, Elsevier, 2018: pp. 773-782.
11. Slavin KV, Wess C. Trigeminal branch stimulation for intractable neuropathic pain: Technical note. *Neuromodulation* 2005; 8:7-13.
12. Abejon D, Deer T, Verrills P. Subcutaneous stimulation: How to assess optimal implantation depth. *Neuromodulation* 2011; 14:343-347.
13. Ellis JA, Mejia Munne JC, Winfree CJ. Trigeminal branch stimulation for the treatment of intractable craniofacial pain. *J Neurosurg* 2015; 123:283-288.
14. Head J, Mazza J, Sabourin V, Turpin J, Hoelscher C, Sharan A. Waves of pain relief: A systematic review of clinical trials in spinal cord stimulation waveforms for the treatment of chronic neuropathic low back and leg pain [published online ahead of print July 30, 2019]. *World Neurosurg* 2019; 131:264-274. doi:10.1016/j.wneu.2019.07.167.

15. Deer TR, Mekhail N, Provenzano D, et al. The appropriate use of neurostimulation: Avoidance and treatment of complications of neurostimulation therapies for the treatment of chronic pain. *Neuromodulation* 2014; 17:571-598.
16. Lee MW, McPhee RW, Stringer MD. An evidence-based approach to human dermatomes. *Clin Anat* 2008; 21:363-373.
17. De Agostino R, Federspiel B, Cesnulis E, Sandor PS. High-cervical spinal cord stimulation for medically intractable chronic migraine. *Neuromodulation* 2015; 18:289-296.
18. Wolter T, Kiemen A, Kaube H. High cervical spinal cord stimulation for chronic cluster headache. *Cephalalgia* 2011; 31:1170-1180.
19. Velasquez C, Tambirajoo K, Franceschini P, Eldridge PR, Farah JO. Upper cervical spinal cord stimulation as an alternative treatment in trigeminal neuropathy. *World Neurosurg* 2018; 114:e641-e646.
20. Arcioni R, Palmisani S, Mercieri M, et al. Cervical 10 kHz spinal cord stimulation in the management of chronic, medically refractory migraine: A prospective, open-label, exploratory study. *Eur J Pain* 2016; 20:70-78.
21. Lambru G, Trimboli M, Palmisani S, Smith T, Al-Kaisy A. Safety and efficacy of cervical 10 kHz spinal cord stimulation in chronic refractory primary headaches: A retrospective case series. *J Headache Pain* 2016; 17:66.
22. Deer T, Slavin KV, Amirdelfan K, et al. Success using neuromodulation with BURST (SUNBURST) study: Results from a prospective, randomized controlled trial using a novel burst waveform. *Neuromodulation* 2018; 21:56-66.
23. Le Doare K, Akerman S, Holland PR, et al. Occipital afferent activation of second order neurons in the trigeminocervical complex in rat. *Neurosci Lett* 2006; 403:73-77.
24. Bartsch T, Goadsby PJ. Increased responses in trigeminocervical nociceptive neurons to cervical input after stimulation of the dura mater. *Brain* 2003; 126:1802-1813.
25. Luz LL, Fernandes EC, Dora F, Lukoyanov NV, Szucs P, Safronov BV. Trigeminal A $\delta$ - and C-afferent supply of lamina I neurons in the trigeminocervical complex. *Pain* 2019; 160:2612-2623.
26. Bartsch T, Goadsby PJ. The trigeminocervical complex and migraine: Current concepts and synthesis. *Curr Pain Headache Rep* 2003; 7:371-376.
27. Barakos JA, D'Amour PG, Dillon WP. Trigeminal sensory neuropathy caused by cervical disk herniation. *AJNR Am J Neuroradiol* 1990; 11:609.
28. Bogduk N. Cervicogenic headache: Anatomic basis and pathophysiologic mechanisms. *Curr Pain Headache Rep* 2001; 5:382-386.
29. Ward TN, Levin M. Headache caused by a spinal cord stimulator in the upper cervical spine. *Headache* 2000; 40:689-691.
30. Castien R, De Hertogh W. A neuroscience perspective of physical treatment of headache and neck pain. *Front Neurol* 2019; 10:1-10.
31. Bartsch T, Goadsby PJ. Stimulation of the greater occipital nerve induces increased central excitability of dural afferent input. *Brain* 2002; 125:1496-1509.
32. Lyubashina OA, Pantelev SS, Sokolov AY. Inhibitory effect of high-frequency greater occipital nerve electrical stimulation on trigeminovascular nociceptive processing in rats. *J Neural Transm* 2017; 124:171-183.
33. Bergerot A, Holland PR, Akerman S, et al. Animal models of migraine: Looking at the component parts of a complex disorder. *Eur J Neurosci* 2006; 24:1517-1534.
34. Piovesan EJ, Kowacs PA, Oshinsky ML. Convergence of cervical and trigeminal sensory afferents. *Curr Pain Headache Rep* 2003; 7:377-383.
35. O'Connor TP, van der Kooy D. Pattern of intracranial and extracranial projections of trigeminal ganglion cells. *J Neurosci* 1986; 6:2200-2207.
36. Storer RJ, Akerman S, Goadsby PJ. GABA receptors modulate trigeminovascular nociceptive neurotransmission in the trigeminocervical complex. *Br J Pharmacol* 2001; 134:896-904.
37. Meuwissen KPV, Gu JW, Zhang TC, Joosten EAJ. Conventional-SCS vs. burst-SCS and the behavioral effect on mechanical hypersensitivity in a rat model of chronic neuropathic pain: Effect of amplitude. *Neuromodulation* 2018; 21:19-30.
38. Meuwissen KPV, de Vries LE, Zhang TC, Gu JW, Joosten EAJ. Burst and tonic spinal cord stimulation both activate spinal GABAergic mechanisms to attenuate pain in a rat model of chronic neuropathic pain [published online ahead of print August 19, 2019]. *Pain Pract* 2019; 20:75-87. doi.org/10.1111/papr.12831.

