

Received: 2019-08-26
Accepted: 2019-10-11
Published: 2020-05-29

CASE REPORT: POSTHERNIORRHAPHY PAIN FROM MUSCLE CALCIFICATION

Naum Shaparin, MD¹
Sarang Koushik, MD²
Sayed Wahezi, MD¹
Karina Gritsenko, MD¹

Background: Inguinal hernia repair is a commonly performed surgical procedure. Surgical repair is a widely accepted treatment option as a corrective measure for inguinal hernias, but it is not without its potential for complications, including chronic postinguinal herniorrhaphy pain. Neuropathic pain, which is the result of nerve damage during inguinal herniorrhaphy, can be caused by compression, irritation, or entrapment by sutures, staples, mesh, tacks, or prosthetic material. It can also occur secondary to periosteal reactions or by actual nerve injuries, such as neurapraxia, axonotmesis, neurotmesis, or complete transection, which can cause end neuroma formation and pain. Nociceptive pain, however, can occur as a result of inflammatory changes at the surgical site leading to chronic pain. Foreign bodies, such as mesh, sutures, and staples, are all possible triggers for the inflammatory reaction.

Case Report: Ultrasound (US) is a noninvasive and affordable diagnostic tool that showed benefit in identifying dystrophic calcification as a potential cause for postinguinal herniorrhaphy chronic pain. It is also used to successfully guide the administration of local pharmacologic agents to control this pain. Use of US in this case allowed us to detect the densely calcified part of the abdominal wall muscles as a hyperechoic area at the surgical bed. The ability of US to detect calcification is not limited to macroscopic calcification only. It was also found to be useful in early detection of microscopic calcification in certain musculoskeletal conditions.

Conclusion: We suggest that US should be considered routinely in the evaluation of cases of postinguinal herniorrhaphy chronic pain.

Key words: Postherniorrhaphy pain, neuropathic pain, muscle calcification, radiofrequency ablation, ultrasound

From: ¹Montefiore Medical Center of the Albert Einstein College of Medicine, Bronx, NY; Department of Anesthesiology Keck School of Medicine of University of Southern California, Los Angeles, CA

Corresponding Author: Sarang Koushik, MD, Department of Anesthesiology Keck School of Medicine of University of Southern California 1450 San Pablo Street Los Angeles, CA 90033

E-mail: sarang.koushik@gmail.com

Conflict of Interest: None Declared

Disclaimer: There was no external funding in the preparation of this manuscript. Conflict of interest: Each author certifies that he or she, or a member of his or her immediate family, has no commercial association (i.e., consultancies, stock ownership, equity interest, patent/licensing arrangements, etc.) that might pose a conflict of interest in connection with the submitted manuscript.

BACKGROUND

Inguinal hernia repair is a commonly performed surgical procedure. Although its true incidence is not known, according to the National Center for Health Statistics Survey, 770,000 inguinal hernias were repaired in 2003 in the United States, making it one of the most common general surgical procedures (1). Surgical repair is not without its potential for complications, including chronic postinguinal herniorrhaphy pain. The following case describes a patient in which ultrasound (US) was successfully used in the identification of calcified abdominal wall musculature at the surgical site. This exposed the neuropathic etiology of the patient's postinguinal herniorrhaphy pain, which allowed successful treatment.

CASE REPORT

A young man who was status post right inguinal herniorrhaphy presented to the pain clinic with 4 years of progressive right-sided inguinal pain. A second surgery did not improve his symptoms. He described the pain as burning and shooting primarily in the right groin, with radiation into the right back and thigh. Tenderness was present over the area and was exacerbated with pressure, prolonged sitting, straining, standing from the supine position, or any motion that involved contraction of the abdominal wall musculature, particularly on the right side.

The patient failed medication trials, including gabapentin 800 mg TID, baclofen 10 mg TID, over-the-counter ibuprofen, capsaicin 0.025% topical ointment, diclofenac patch 1.3%, and tramadol 50 to 100 mg QID. At an outside institution, the patient received 2 "blind" right-sided ilioinguinal nerve blocks using anatomic landmarks with moderate relief for 3 days. Subsequently, pulsed radiofrequency ablation of the right ilioinguinal nerve was performed with 3 days of relief. On presentation to our pain center, the decision was made to reevaluate the area using ultrasonography prior to proceeding with further management. During examination, a 2- x 3-cm hyperdense area consistent with a muscular calcification in close proximity to the abdominal wall by the right ilioinguinal nerve was noted. After the patient's usual pain location was reconfirmed, a 25-gauge needle was placed into the calcified area of the right oblique muscle with an in-plane approach under direct US-guided visualization (Fig. 1). Four milliliters of 0.5% bupivacaine and 40 mg of Kenalog (Bristol-Myers Squibb, Lawrence, NJ) were injected. Following the procedure, the patient reported

almost complete resolution of his pain. At the 1-month follow-up, the patient continued to have almost complete resolution of pain, and at the 3-month follow-up, the patient had 70% relief of pain.

DISCUSSION

Chronic postoperative pain may be classified into 1 of 3 categories: (1) neuropathic pain (secondary to nerve injury), (2) nociceptive pain (secondary to inflammatory changes in the surgical site), or (3) a combination of both types of pain (1,2). Although this classification exists, in reality it may be challenging to clinically identify the actual source of pain. This may in turn lead to undertreatment of the actual pain trigger. Neuropathic pain, which is the result of nerve damage during inguinal herniorrhaphy, can be caused by compression, irritation, or entrapment by sutures, staples, mesh, tacks, or prosthetic material. It can also occur secondary to periosteal reactions or by actual nerve injuries, such as neurapraxia, axonotmesis, neurotmesis, or complete transection, which can cause end neuroma formation and pain. Nociceptive pain, however, can occur as a result of inflammatory changes at the surgical site leading to chronic pain. Foreign bodies, such as mesh, sutures, and staples, are possible triggers for the inflammatory reaction (3).

Multiple nerves are found in the inguinal region, including the ilioinguinal, iliohypogastric, femoral, obturator, genital and cutaneous branches of the genitofemoral nerve, and the lateral femoral cutaneous nerve of the thigh. Depending on the surgical technique used in the herniorrhaphy, whether open or laparoscopic, one or more of these nerves may be injured (4,5). Rosenberger et al (5) found that the lateral femoral cutaneous nerve was the most frequently entrapped (58%), followed by the genitofemoral nerve (31% for the femoral branch and 4% for the genital branch), and finally by the ilioinguinal nerve (4.1%). It is difficult to determine which of these nerves is the source of injury in part owing to the shared segmental origin from the spinal cord (lower thoracic/upper lumbar segments), and partly due to their peripheral communication and overlap in their respective areas of innervation (3).

Since the introduction of US technology to the medical field in the 1980s, it has been extensively used in the evaluation of inflammatory, degenerative, neoplastic, and cystic causes of pain. Because of its ability to magnify small structures and to visually differentiate

anatomic components of an affected area, it has aided in the detection and localization of many pathological conditions (6,7). Nerve entrapment, tendosynovitis, joint effusions and arthritis, bursitis, ligament disease, and cysts are just a few examples of painful conditions that can be diagnosed using US (6).

Tissue disruption, such as disease, trauma, or aging, is often needed for dystrophic calcification to occur (8). Bonucci and Sadun (9) conducted an experiment, in which calcification in rats' gastrocnemius muscle was noticed 36 hours after the applied trauma (prolonged massage to the muscle). Calcification occurred in more than one microscopic structure within each single muscle fiber, including the sarcoplasmic reticulum, myofibrils, and mitochondria. In the same study, the degree of calcification was found to be proportionate to the severity of the trauma applied (9). This calcification can be the

source of pain secondary to compression on or irritation of the surrounding muscles and tissue.

CONCLUSIONS

In the present case, by using US, we were able to detect the densely calcified part of the abdominal wall muscles as a hyperechoic area at the surgical bed (Fig. 1). This area was easily differentiated from the surrounding less echoic muscles and soft tissue. The ability of US to detect calcification is not limited to macroscopic calcification only. It was also found to be useful in early detection of microscopic calcification in certain musculoskeletal conditions in which other radiographic modalities (x-ray, magnetic resonance imaging) failed to do so (10). We suggest that US should be considered routinely in the evaluation of cases of postinguinal herniorrhaphy chronic pain.

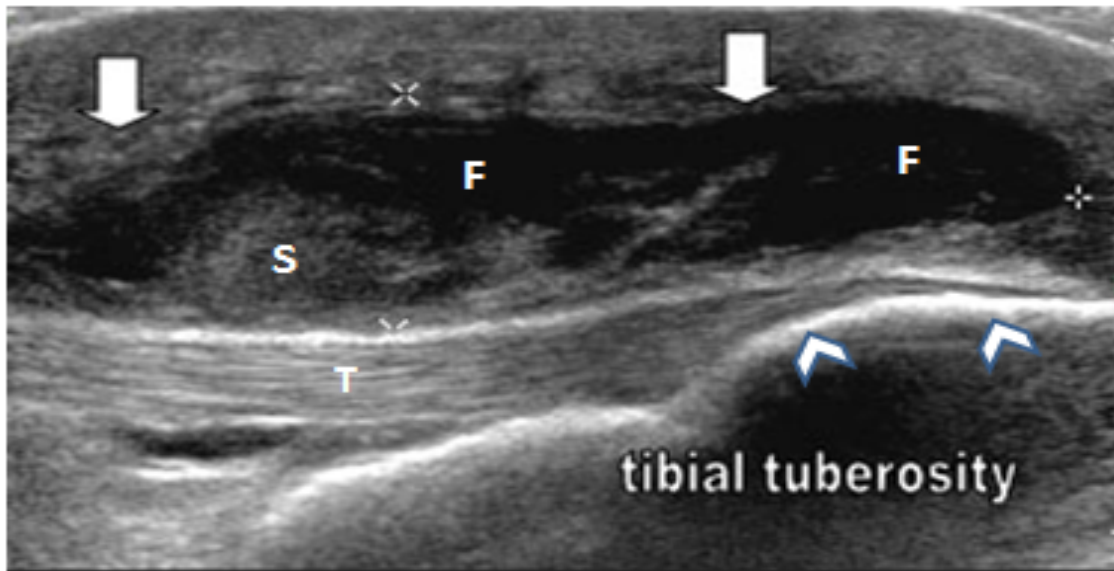


Fig. 1. Showing Hyper-echoic tibial tuberosity (arrow heads) and infrapatellar bursa (arrows) distended by hypo-echoic synovial hypertrophy and by anechoic (dark/black) fluid.
T, patellar tendon; S, synovial hypertrophy; F, fluid

REFERENCES

1. Linderöth G, Kehlet H, Aasvang EK, Werner MU. Neurophysiological characterization of persistent pain after laparoscopic inguinal hernia repair. *Hernia* 2011; 15:521-529.
2. Kalliomäki ML, Meyerson J, Gunnarsson U, Gordh T, Sandblom G. Long-term pain after inguinal hernia repair in a population-based cohort; Risk factors and interference with daily activities. *Eur J Pain* 2008; 12:214-225.
3. Amid PK. Causes, prevention, and surgical treatment of postherniorrhaphy neuropathic inguinodynia: Triple neurectomy with proximal end implantation. *Hernia* 2004; 8:343-349.
4. Stark E, Oestreich K, Wendl K, Rumstadt B, Hagmüller E. Nerve irritation after laparoscopic hernia repair. *Surg Endosc* 1999; 13:878-881.
5. Rosenberger RJ, Loeweneck H, Meyer G. The cutaneous nerves encountered during laparoscopic repair of inguinal hernia: New anatomical findings for the surgeon. *Surg Endosc* 2000; 14:731-735.
6. Hashefi M. Ultrasound in the diagnosis of noninflammatory musculoskeletal conditions. *Semin Ultrasound CT MR* 2011; 32:74-90.
7. Kane D, Balint PV, Gibney R, Bresnihan B, Sturrock RD. Differential diagnosis of calf pain with musculoskeletal ultrasound imaging. *Ann Rheum Dis* 2004; 63:11-14.
8. Giachelli CM. Ectopic calcification: Gathering hard facts about soft tissue mineralization. *Am J Pathol* 1999; 154:671-675.
9. Bonucci E, Sadun R. An electron microscope study on experimental calcification of skeletal muscle. *Clin Orthop Relat Res* 1972; 88:197-217.
10. Backhaus M, Kamradt T, Sandrock D, et al. Arthritis of the finger joints: A comprehensive approach comparing conventional radiography, scintigraphy, ultrasound, and contrast-enhanced magnetic resonance imaging. *Arthritis Rheum* 1999; 42:1232-1245.